

---

# Technical note : Endoscopic Transchoroidal Fissure Approach

---

*Mohamed Si Saber, Sofiane Imekraz, Kheireddine A. Bouyoucef*

Department of Neurosurgery, University Hospital of Blida, Algiers, Algeria

## Abstract

The third ventricle is one of the most difficult areas in the brain to access surgically. It is almost impossible to reach its cavity without incising some neural and vascular structures. Many microsurgical approaches are described and known by neurosurgeons, namely the trans-callosal (anterior, middle & posterior), trans-cortical trans-ventricular, trans-lamina terminalis, inter-forniceal and trans-sphenoidal.

In recent years, neuro-endoscopic procedures are increasingly used and preferred because of their feasibility and efficacy. The endoscopic approach towards tumors located in the pineal region is particularly a case in point, as this technique permits simultaneous treatment of hydrocephalus frequently encountered as well as tumor biopsy under direct vision, and the possibility of establishing an appropriate therapeutic strategy.

We describe a purely endoscopic technique passing through the choroidal fissure located between the fornix and the thalamus in order to approach the pineal region and posterior fossa tumors which are invisible through the foramen of Monro.

The use of this endoscopic approach avoids much neurological morbidity (memory loss and psychiatric disturbances) due, respectively, to the damage to the body of the fornix and the thalamus.

Out of 1800 neuroendoscopic procedures, 390 were performed for intraventricular lesions, being a total of 174 tumors located in the posterior compartment amongst which 124 were at the posterior pole of the third ventricle and 50 were in the posterior fossa. Out of these were 23 purely endoscopic transchoroidal approaches for tumors located at the pineal region and posterior fossa. No mortality and considerably lower morbidity resulted than from other methods.

Using our approach, the massa intermedia is well seen. This marks the boundary between the processes of the anterior part of the third ventricle which must be approached by the foramen of Monro and those involved the pineal region and the aqueduct of Sylvius arising to the fourth ventricle or brainstem by the choroidal fissure approach.

The purely endoscopic Transchoroidal fissure approach is a safe, effective and minimally invasive surgical technique and constitutes a better alternative for reaching the pineal region and posterior fossa tumors. In this way it is possible at one step to treat any associated hydrocephalus under direct vision, study the CSF and obtain a histological diagnosis. Thus, ventriculo-peritoneal shunt procedures with all their complications are avoided, difficult and at times imprecise stereotactic biopsy become unnecessary, and potentially unnecessary large open surgery is rendered irrelevant.

## Introduction

Access routes to lesions of the third ventricle (V3), the deeper brain structure, are multiple. They depend on their location and nature as well as the preference and experience of the neurosurgeon. These approaches may be achieved microsurgically and /or assisted by endoscopy or purely endoscopically (Figure 1). Schematically, the main routes are the following:

- High routes: trans-callosal (anterior, middle or posterior), trans-cortical transventricular, inter-thalamotrigonal, supra-cerebellar
- Transbasal routes: bilateral subfrontal,trans-lamina terminalis, fronto-temporal lateral.
- Low routes: trans-sphenoidal.

Lesions situated in the anterior as well as the posterior part of the third ventricle have heretofore been shunned when considering an endoscopic approach. However, our preference is in fact the endoscopic approach for these lesions in addition to others in more accessible sites.

Whilst access to the tumors located at the anterior part of V3(colloid cyst) is definitely easier by the foramen of Monro, those located at the posterior part, particularly those behind the interthalamic adhesion, are more difficult to access. Consequently we suggest a posterior access, which makes it possible to utilize the whole posterior space of the third ventricle and to remain plumb with the aqueduct of Sylvius. Furthermore this makes it possible to carry out simultaneous Endoscopic Third Ventriculotomy (ETV) in the case of hydrocephalus secondary to the tumors of the fourth ventricle, and to take biopsies of posterior fossa tumors.

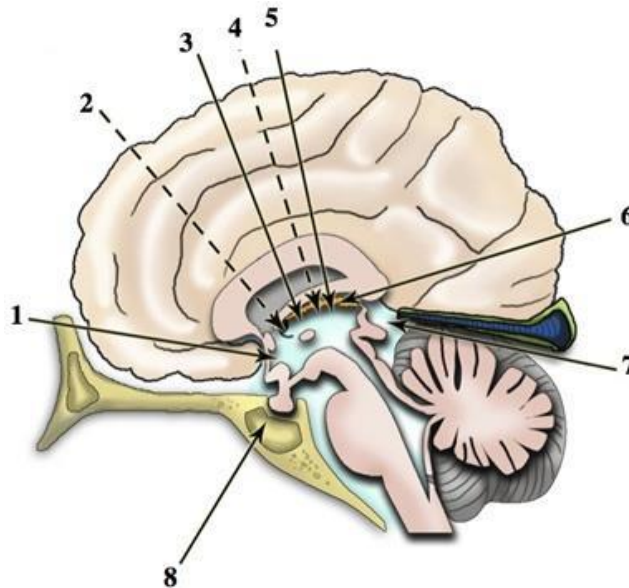


Figure 1. The different approaches to the third ventricle; 1: Subfrontal trans-lamina terminalis; 2: Trans-cortical transforaminal; 3: Anterior trans-callosal; 4: Transcortical Transchoroidal; 5: Middle trans-callosal; 6: Posterior trans-callosal; 7: Occipital supra-cerebellar; 8: Trans-sphenoidal.

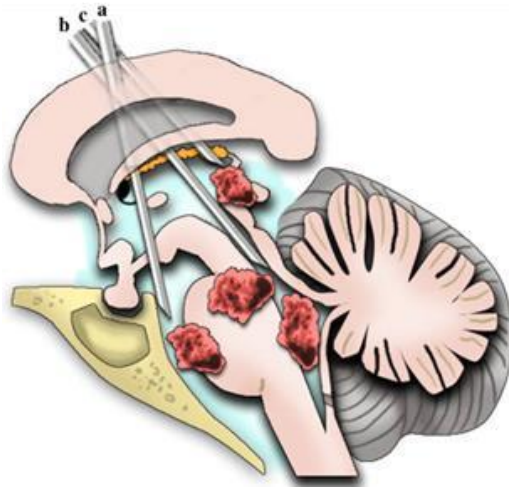


Figure 2. Endoscopic approach to the posterior part of the third ventricle (V3) and fourth ventricle (V4) tumors; a: Endoscopic Transchoroidal or trans-foraminal approach to the brainstem tumors via the ostomy of an endoscopic third ventriculostomy (ETV); b: Endoscopic Transchoroidal approach to intra-axial brainstem and V4 tumors via the aqueduct of Sylvius; c: Endoscopic Transchoroidal approach to tumors of the pineal region.

We describe a purely endoscopic approach for access to the pineal and the posterior fossa tumors (fourth ventricle (V4) & brainstem), which uses a transchoroidal route through the choroidal fissure. (Figures 2 and 3). This route is known to neurosurgeons using microscopic techniques as the inter-thalamo-trigonal approach, and it is this route which we have adapted for pure endoscopic techniques.

Crossing the foramen of Monro in a more traditional approach has the disadvantage of missing a tumor located behind the interthalamic adhesion. Furthermore, to incline the endoscope forward to visualize such a tumor may cause trauma to the choroid plexus, the anterior pillar of the fornix, the interthalamic adhesion, and the peri-aqueductal structures at the periphery of the wound. Injury to the latter may result in bilateral ophthalmoplegia owing to damage to the oculomotor nerve nuclei in the peri-aqueductal gray matter. Injury to the interthalamic adhesion results in collateral effects on memory. These risks are substantially reduced in our approach.

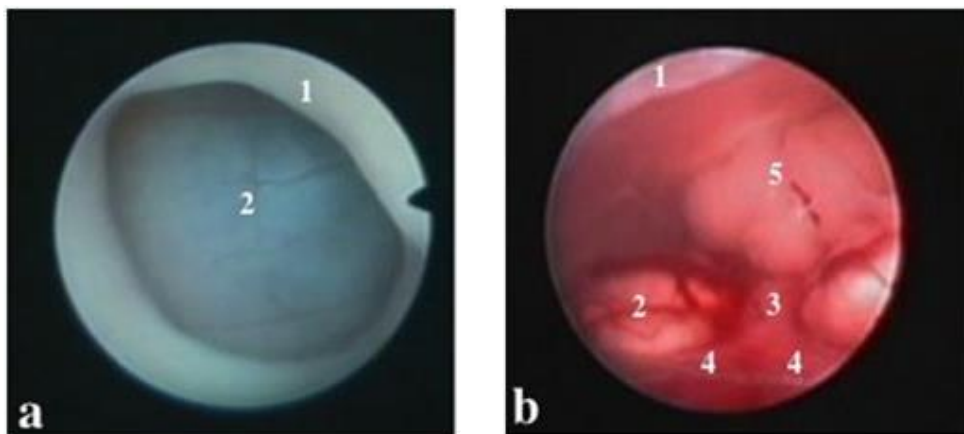


Figure 3. Endoscopic approach to the posterior part of third ventricle (V3) and fourth ventricle (V4) tumors; a: via the cerebral aqueduct often dilated by hydrocephalus, 1: cerebral aqueduct, 2: tumor; b: via the ostomy after treatment of hydrocephalus by ETV, 1: clivus, 2: protuberance, 3: basilar artery, 4: posterior cerebral artery, 5: tumor.

# Anatomy

## Microsurgical

A perfect knowledge of the richness of neural and vascular structures in this deep region of the brain is mandatory for the neurosurgeon if numerous complications of surgical intervention are to be avoided.

The choroidal fissure is part of the medial wall of the lateral ventricles. It is a C-shaped structure with a ventral concavity (Figures 4 and 5). It begins at the inter-ventricular foramen, continues through the body and atrium, and ends in the temporal horn. Its termination is called the inferior choroidal point [1].

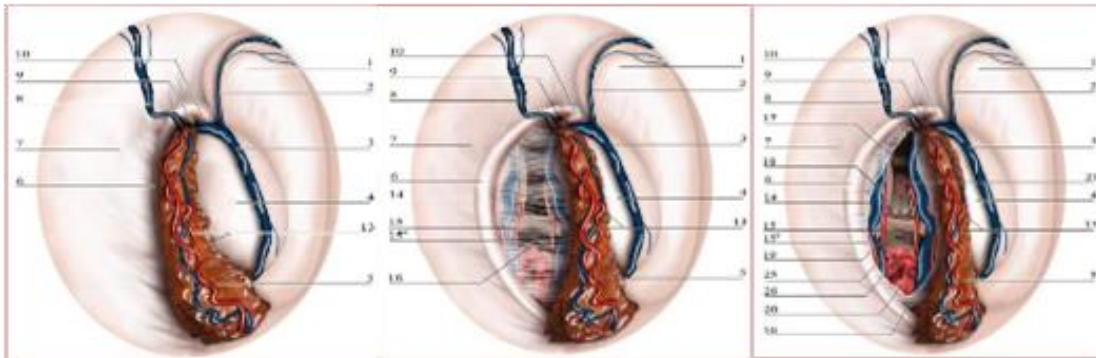


Figure 4. The choroidal fissure; 1: Caudate nucleus; 2: Anterior caudate vein; 3: Thalamo-striate vein; 4: Thalamus; 5: Choroid plexus; 6: Body of the fornix; 7: Septum pellucidum; 8: Septal vein; 9: Foramen of Monro; 10: Column of the fornix; 11: Tenia thalami; 12: Tenia fornix; 13: Choroidal vessels; 14: Internal cerebral vein; 15: Lateral posterior choroidal artery; 16: Tela choroidea; 17: Optic chiasm; 18: Mamillary bodies; 19: Massa intermedia; 20: Tumor; 21: Infundibular recess; 22: Lateral ventricle; 23: Septum pellucidum; 24: Corpus callosum; 25: Aqueduct; 26: Posterior commissure.

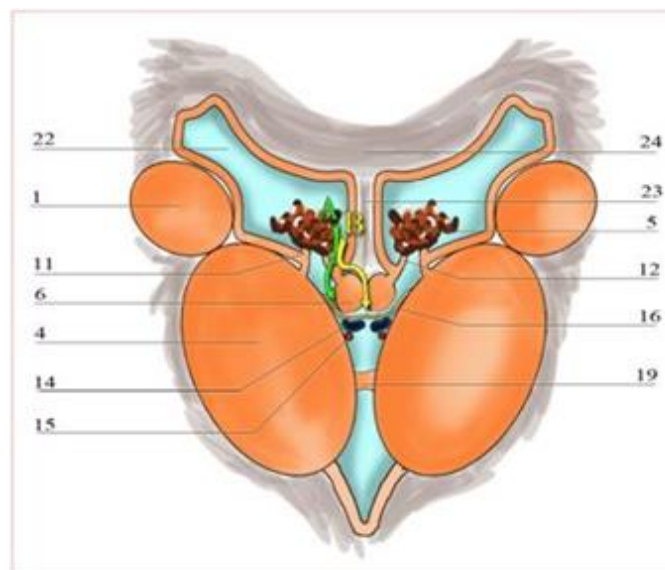


Figure 5. Coronal cut of the choroidal fissure showing the main teniae (fornicis and thalami); 1: Caudate nucleus; 4: Thalamus; 5: Choroid plexus ; 6: Body of the fornix ; 11: Tenia thalami; 12: Tenia fornix; 14: Internal cerebral vein; 15: Medial posterior choroidal artery; 16: Tela choroidea; 19: Massa intermedia; 22: Lateral ventricle; 23: Septum pellucidum; 24: Corpus callosum; A: Transchoroidal approach; B: Interfornical approach.

The choroidal fissure is the site of attachment of the choroid plexus in the lateral ventricles, between the thalamus and the fornix. As the fornix, the choroidal fissure wraps around the thalamus. Therefore, the fornix forms the outer circumference of the choroidal fissure. The choroid plexuses are linked to the thalamus by the taenia choroidea, and to the fornix by the taenia fornicis.

Inside the choroidal fissure run the choroidal arteries. They arise from the posterior cerebral arteries. The medial posterior choroidal arteries vascularize the choroid plexus of the roof of the third ventricle and the body of the lateral ventricle and the lateral posterior choroidal arteries vascularize the choroid plexus of the atrium, body and posterior part of the temporal horn.

The ventricular veins join the deep venous system passing through the choroidal fissure. The lateral group of ventricular veins course through the thalamic (or inner) side of the choroidal fissure, while the medial group of veins course through the forniceal (or outer) side. Veins draining the frontal horn and body of the lateral ventricle empty into the internal cerebral veins (ICV).

The transventricular transchoroidal approaches allow access to the deepest cerebral structures, by minimizing cerebral retraction. Creating an opening through the choroidal fissure along the taenia fornicis is generally preferred because fewer difficulties are encountered than along the taenia choroidea, through which pass many important veins and arteries.

The choroidal fissure (CF) is divided into three portions: rostral (body), dorsal (atrial) and caudal (temporal). The rostral portion of the choroidal fissure is situated in the body of the lateral ventricle, between the body of the fornix and the superior surface of the thalamus. Opening through the CF exposes the roof of the third ventricle and the velum interpositum, a closed space from the foramen of Monro to the area above the pineal body, through which course the internal cerebral veins. The rostral portion of the CF is mainly related to the terminal branches of the medial posterior choroidal arteries and the lateral posterior choroidal artery [2, 3].

## **Endoscopic**

Entry in the right frontal horn of the lateral ventricle reveals first, the choroid plexus which runs from posterior to anterior and lateral to medial, directly reaching the posterior part of the foramen of Monro.

Neuronavigation through a rigid endoscope, with a 5-6mm working channel and 1mm tools, is possible when the ventricles are small. The foramen of Monro is bordered anteriorly by the anterior pillar of the fornix. Seen clockwise from the anterior pillar of the fornix, being the anterior part of the foramen of Monro, at 12 o'clock, are noted in sequence: the bulge of the head of the caudate nucleus, the thalamo-striate vein, the choroid plexus and the superior choroidal vein and finally in the midline, the body of the fornix overlooked at right angle by the septum pellucidum and the anterior septal vein. (this joins the thalamostriate vein at the posterior part of the the foramen of Monro), the superior choroidal vein forming the ICV which will cross the tela choroidea posteriorly to reach the Gallian vein.

The opening of the choroidal fissure between the body of the fornix and the choroid plexus through the taenia fornicis permits direct access to the roof of the third ventricle. The choroid plexus is displaced laterally revealing the tela choroidea (an arachnoid-like membrane) through which are perceived the two internal cerebral veins and the choroidal arteries (latero-posterior and medio-posterior) (Figure 6a), which run through the roof of the third ventricle. Their separation using a balloon (Fogarty No. 4 probe), gives direct access to the posterior chamber revealing anteriorly the inter-thalamic commissure, which marks the boundary between two areas: anteriorly, two mammillary bodies and infundibulum, and posteriorly, the "midbrain", the posterior commissure, the pineal recess, the pineal gland itself and the supra-pineal recess (Figure 6b).

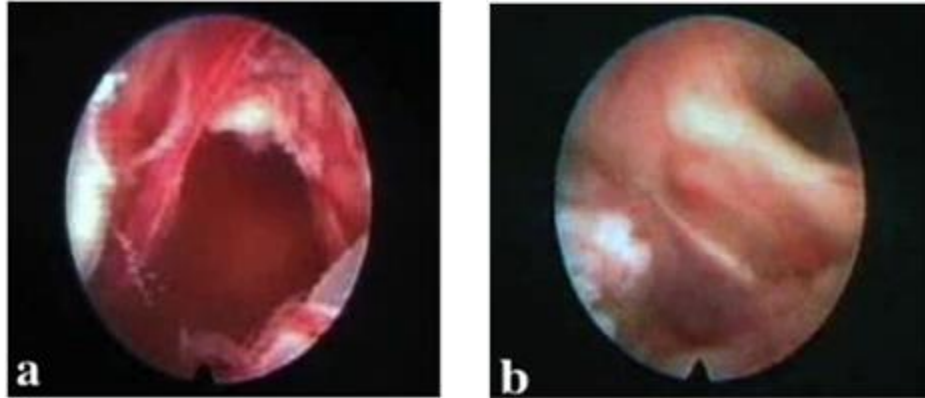


Figure 6. Endoscopic view of the Transchoroidal approach; a: posterior part of the third ventricle (V3) (NB Opening the choroidal fissure allows direct access to the roof of V3 between the internal cerebral veins and choroidal arteries; b: posterior chamber of the third ventricle (V3).

Prolonged irrigation is performed to remove any debris which may obstruct the aqueduct of sylvius.

The ventricles are inflated by Ringer's solution to avoid ingress of air and to prevent ventricular collapse. Furthermore, it is preferable to perform the narrowest possible cortotomy in order to avoid any CSF leak.

## Surgical Technique

With the patient in supine position, the head neutral, a 2cm precoronal incision is made 3cm from the midline. A burr hole is performed, followed by cruciform opening of the dura matter.

A rigid endoscope, 18cm long, 6 mm in diameter and provided with a 0° or 30° lens is introduced into the right lateral ventricle, often dilated by obstructive hydrocephalus.

A sample of CSF is taken to look for tumor cells and for the determination of tumor markers.

The first landmark is the choroid plexus which is a guidepost for the foramen of Monro; it is always helpful to traverse the foramen of Monro by performing ETV and to have a look at the posterior part of V3 if the tumor is visible. If it not, a transchoroidal fissure approach is necessary.

## Endoscopic Transchoroidal Approach

Under visual control, using the coagulator, the choroid plexus is delicately retracted to the thalamus, by stretching its forniceal attachment (taenia fornicis).

An easy fenestration by a simple introduction of the bipolar coagulator is made, until the tela choroidea, which represents the roof of the V3, is visualized. This is then opened. A Fogarty catheter n° 4 is used to open the choroidal fissure, avoiding the vascular structures laterally.

Thus, complete access to the posterior chamber of V3, the pineal region and cerebral aqueduct is achieved easily.

Lesions of the pineal region are easily accessible for biopsy or total resection. Whenever possible, those of the posterior fossa will be approached through the cerebral aqueduct (V4 tumors) or through an ostomy (exophytic brainstem tumor).

## Endoscopic Interforniceal Approach (Figure 7)

This is a variant of the previous approach. Under endoscopic control surgical dissection veers towards the midline at the junction between the septum and the two bodies of the fornix. Fine dissection permits access to the tela choroidea forming the roof of the V3. Opening it with bipolar coagulation gives wide access to V3 after gradual inflation of a balloon. The danger here is risk of damage to the body of the fornix, ICV and choroidal arteries.

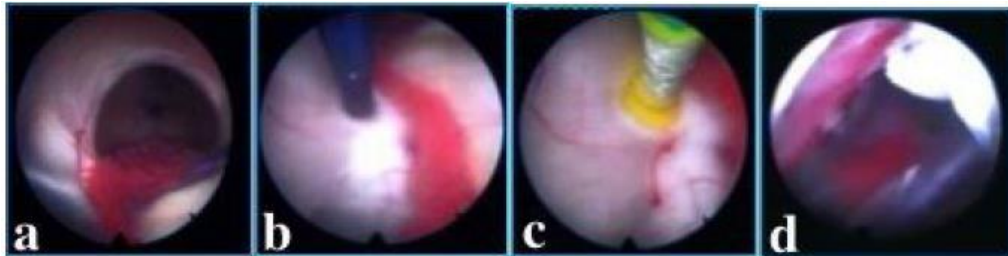


Figure 7. Endoscopic view; a: inside the frontal horn of the right VL showing a dilated foramen of Monro with the main landmarks (septal vein medially, thalamo-striate vein laterally and choroid plexus posteriorly); b: opening the choroidal fissure (taenia fornicis) with a gentle introduction of the coagulator; c: enlargement of the fenestration by balloon inflation; d: opening of the roof of V3 showing the internal cerebral veins and choroidal arteries.

## **Discussion**

A variety of pathologies varying from benign to malignant tumors occurs in the region of the posterior third ventricle and posterior fossa. The complexity of access to this anatomical location makes the management of these lesions a considerable challenge even for the skilled neurosurgeon.

Credit must be awarded to Sir Walter Dandy [4], who pioneered the inter-hemispheric trans-callosal routes to the lateral and third ventricles. In 1921, he described the posterior trans-callosal approach with division of the splenium for removal of pineal tumors, and followed this by reporting a series of third ventricle tumors in 1933. Bush [5] performed the first inter-forniceal approach in 1944. In 1978, Delandsheer & Guiot [6] described a microsurgical inter-thalamotrigonal approach to the third ventricle. In 1998, Wen & al. [7] presented an anatomical study of the choroidal fissure and of the supra- and sub-choroidal surgical routes.

In recent years the endoscopic approach through the foramen of Monro has gained increased popularity for the biopsy and, in selected cases, the removal of tumors of the posterior third ventricle. However, a biopsy of V3 & V4 tumors cannot always be safely accomplished. In fact, in two cases the postoperative result was a complete bilateral ophthalmoplegia that was attributed to peri-aqueductal oculomotor nuclei damage. This was probably due to poor manipulation of the endoscope in relation to the axis of the cerebral aqueduct. To avoid this kind of complication, which was fortunately only transient, we have developed a purely endoscopic inter-thalamotrigonal approach.

Since the first report by Fukushima et al. [8, 9] of an intraventricular method of tumor biopsy, neuro-endoscopy has been increasingly used in the diagnosis and treatment of these tumors. It is widely accepted as an ideal method of diagnosis for intra- or peri-ventricular tumors, which may often cause hydrocephalus [10].

Indeed, in comparison with stereotactic biopsy, endoscopic biopsy has many advantages. By the same minimally invasive approach, through direct vision, it is possible effectively to control tumor bleeding immediately after biopsy, and more importantly, to manage associated hydrocephalus as well as perform CSF analysis (alpha fetoprotein: AFP, human chorionic gonadotrophin: HCG, and others tumor markers). We prefer the use of the rigid endoscope rather than the flexible, because the latter is difficult to handle and its picture quality is inferior.

These procedures eliminate the need for ventriculo-peritoneal shunting and thus avoid its complications. The diagnostic yield by stereotactic biopsy is around 94% [6, 11]. The disadvantages include a relatively higher risk of bleeding, an 8% morbidity, in addition to an increased mortality which has been reported for pineal tumors (1,3- 1,9%) compared to other regions (0,81%) [6, 11].

Open microsurgery, especially using the trans-cortical and trans-callosal routes for intra- or peri-ventricular tumors of the posterior fossa carries severe morbidity [12, 13] and cumulative postoperative mortality. These use the same corridors to reach the third ventricle (para-/interforaminal, supra-/subchoroidal) as endoscopy but their significant morbidity is from 5% to 15% [14]. The most important issue in this approach is the management of the veins and the fornices. Excessive retraction, manipulation or injury (mechanical damage) will cause, respectively, thrombosis and permanent postoperative loss memory. Thus the learning curve for this type of surgery is steeper than that of the endoscopic approach.

Furthermore, in cases of malignant tumors, even extensive surgical resection does not eliminate the need for subsequent adjuvant therapy [15]. A substantial number of neoplasms, including germinomas, malignant non-germinomatous germ cell tumors, pineal parenchymal neoplasms, diffuse brainstem gliomas, and metastases can, however, be successfully managed without surgical intervention, using radio- and/or chemo-therapy [16].

By contrast, the surgeon is sometimes very frustrated to come face to face with a tumor, especially if benign, when he cannot completely remove it. The manufacture of an ultrasonic aspirator adapted to neuro-endoscopic surgery is eagerly sought.

In the department of neurosurgery of the University of Blida (Algeria), the strategies used for the treatment of the tumors located in the pineal region is summarized in Figure 8.



From 1994 to September 2012, 1800 neuroendoscopic procedures were performed in our department. Among which 390 were for intraventricular lesions including 174 located in the posterior compartment (pineal region, posterior fossa, V4 and brainstem). The results are summarized in Tables 1 and 2.

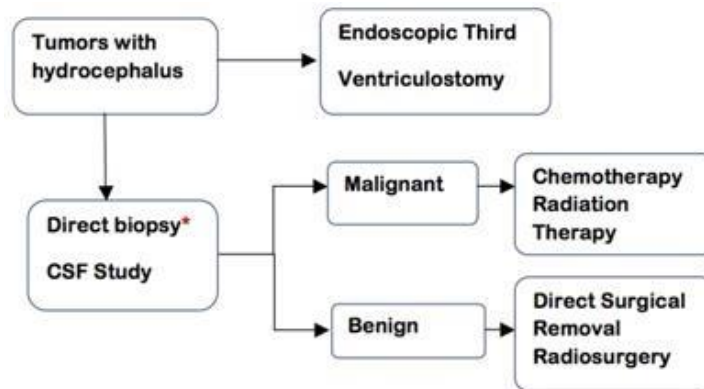


Figure 8. Management decision making for pineal tumors; \*: Intra-operative histological examination is necessary to help the neurosurgeon to take a decision whether to continue surgical intervention or not.

**Table 1. Pineal region**

Pineal regions tumors	N = 124
Germinomas	26
Pinealoblastomas	13
Pinealocytomas	4
Anaplastic astrocytomas	3
Ependymomas	11
Oligodendrogliomas	1
low grade astrocytomas	24
Not Conclusive	34
Lost	8

**Table 2. Posterior fossa region**

Posterior fossa tumors	N = 50
Medulloblastomas	16
Astrocytomas III	1
low grade astrocytomas	19
Ependymomas	12
Not conclusive	2

Our results demonstrate the potential value of the endoscopic Transchoroidal and inter-forniceal approaches for pineal region tumors. With this method, CSF analysis, ETV, biopsy under direct vision and intra-operative histological sampling are all possible at one step.

Furthermore, with the same approach we have performed biopsies for tumors located in V4 (n=36) and for exuberant brainstem tumors through an ostomy (n=6) or aqueduct (n=8).

There was no mortality in our series, whilst morbidity was 4/124 owing to trauma to the interthalamic adhesion but without neurological consequences.

When we tried to reach tumors located in V4 through the foramen of Monro, two patients developed complete ophthalmoplegia, which was fortunately transient. However, the subsequent transchoroidal endoscopic approach (n=23) resulted in no complications.

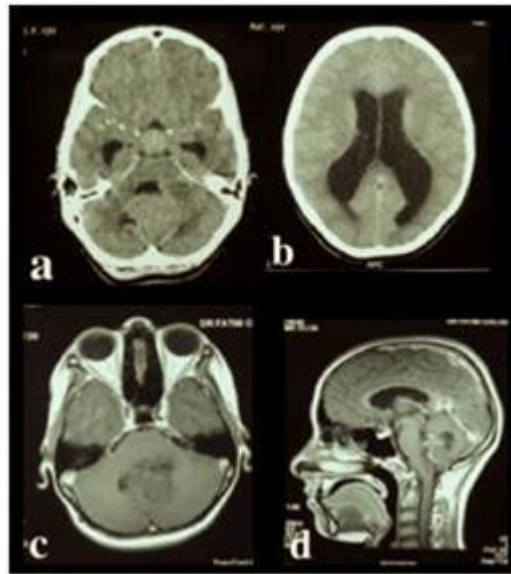


Figure 9. Thirteen year old patient with a medulloblastoma with suprasellar metastasis, having ETV and endoscopic biopsy via the aqueduct; a, b: Axial planes CT-scan imaging showing :a: midline cerebellar mass posterior to V4 ventricle and suprasellar mass associated with, b: hydrocephalus ; c: Axial T1- weighted MR imaging after gadolinium injection showing a midline cerebellar mass posterior to V4 ventricle; d: Sagittal T1-weighted MR imaging after gadolinium injection showing a midline cerebellar mass with posterior compression of the brain stem and the suprasellar metastasis.

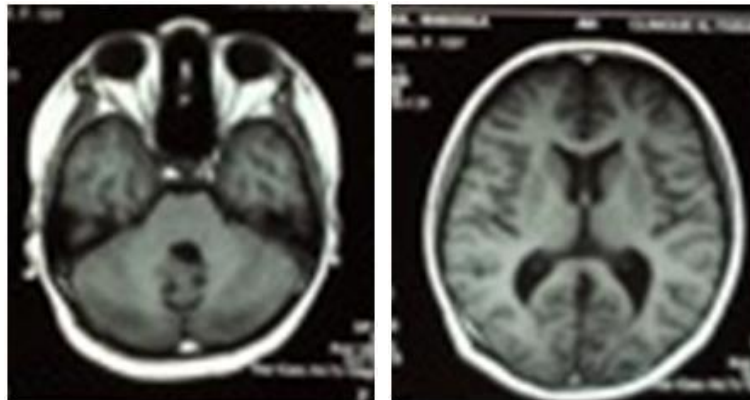


Figure 10. The same patient after 3 years without open surgery, having been treated only by radio- and chemo-therapy, Axial T1 weighted images showing the absence of lesions and complete remission of hydrocephalus.

From the data provided (tables 1 and 2), the number of unfruitful pathological results after biopsy might seem high. However, in these cases, biopsy fragments were deemed inadequate by the pathologist to permit substantive conclusions. We therefore highlight the paramount importance of maintaining close cooperation between pathologists and neurosurgeons in order to ensure favourable results.

Our algorithm for treatment of tumors of pineal region is shown. We believe that the same algorithm could be used for many high risk tumors located in the posterior fossa such as medulloblastoma, for example.

In fact, since 2005 we have obtained surprisingly good results after only radio- and chemo-therapy (without open surgery) with only endoscopic tumor biopsy (Figures 9 and 10).

## Conclusion

The endoscopic Transchoroidal approach is an effective, safe and less invasive technique for tumors located in the pineal region and the posterior fossa. Doubtless, such surgery has a steep learning curve, but not necessarily steeper than the traditional open approach. Furthermore, using the same minimally invasive procedure three procedures are possible simultaneously: CSF Study, ETV and tumor biopsy. Thus the risks of stereotaxy and VP shunting are circumvented.

## Acknowledgments

For help with scientific editing and, other valuable advice, the authors thank Dr. Mahmoud Messerer of the Department of neurosurgery of Centre Hospitalier Universitaire Vaudois, Lausanne, Switzerland, and, Dr Julie Dubourg of the Hospices Civils de Lyon, France.

## References

- [1] Nagata S, Rhoton AL, Jr., Barry M. Microsurgical anatomy of the choroidal fissure. *Surgical neurology*. 1988; 30(1): 3-59. Epub 1988/07/01.
- [2] Rhoton AL, Jr., Yamamoto I, Peace DA. Microsurgery of the third ventricle: Part 2. Operative approaches. *Neurosurgery*. 1981; 8(3): 357-73. Epub 1981/03/01.
- [3] Hamlat A, Morandi X, Riffaud L, Carsin-Nicol B, Haegelen C, Helal H, et al. Transtemporal-transchoroidal approach and its transamygdala extension to the posterior chiasmatic cistern and diencephalo-mesencephalic lesions. *Acta neurochirurgica*. 2008; 150(4): 317-27; discussion 27-8. Epub 2008/03/04.
- [4] Dandy WE. *Benign tumors in the third ventricle of the brain; diagnosis and treatment*. Springfield, Charles C Thomas; 1933.
- [5] Busch E. A new approach for the removal of tumors of the third ventricle. *Acta Psychiatr. Scand*. 1944; 19:57-60.
- [6] Regis J, Bouillot P, Rouby-Volot F, Figarella-Branger D, Dufour H, Peragut JC. Pineal region tumors and the role of stereotactic biopsy: review of the mortality, morbidity, and diagnostic rates in 370 cases. *Neurosurgery*. 1996; 39(5): 907-12; discussion 12-4. Epub 1996/11/01.
- [7] Wen HT, Rhoton AL, Jr., de Oliveira E. Transchoroidal approach to the third ventricle: an anatomic study of the choroidal fissure and its clinical application. *Neurosurgery*. 1998; 42(6): 1205-17; discussion 17-9. Epub 1998/06/19.
- [8] Fukushima T. Endoscopic biopsy of intraventricular tumors with the use of a ventriculofiberscope. *Neurosurgery*. 1978; 2(2): 110-3. Epub 1978/03/01.
- [9] Fukushima T, Ishijima B, Hirakawa K, Nakamura N, Sano K. Ventriculofiberscope: a new technique for endoscopic diagnosis and operation. Technical note. *Journal of neurosurgery*. 1973; 38(2): 251-6. Epub 1973/02/01.
- [10] O'Brien DF, Javadpour M, Collins DR, Spennato P, Mallucci CL. Endoscopic third ventriculostomy: an outcome analysis of primary cases and procedures performed after ventriculoperitoneal shunt malfunction. *Journal of neurosurgery*. 2005; 103(5 Suppl): 393-400. Epub 2005/11/24.
- [11] Kreth FW, Schatz CR, Pagenstecher A, Faist M, Volk B, Ostertag CB. Stereotactic management of lesions of the pineal region. *Neurosurgery*. 1996; 39(2): 280-9;

- discussion 9-91. Epub 1996/08/01.
- [12] Ellenbogen RG, Moores LE. Endoscopic management of a pineal and suprasellar germinoma with associated hydrocephalus: technical case report. *Minimally invasive neurosurgery* : MIN. 1997; 40(1): 13-5; discussion 6. Epub 1997/03/01.
  - [13] Yamini B, Refai D, Rubin CM, Frim DM. Initial endoscopic management of pineal region tumors and associated hydrocephalus: clinical series and literature review. *Journal of neurosurgery*. 2004; 100(5 Suppl Pediatrics): 437-41. Epub 2004/08/04.
  - [14] Matsutani M, Sano K, Takakura K, Fujimaki T, Nakamura O, Funata N, et al. Primary intracranial germ cell tumors: a clinical analysis of 153 histologically verified cases. *Journal of neurosurgery*. 1997; 86(3): 446-55. Epub 1997/03/01.
  - [15] Oi S, Kamio M, Joki T, Abe T. Neuroendoscopic anatomy and surgery in pineal region tumors: role of neuroendoscopic procedure in the 'minimally-invasive preferential' management. *Journal of neuro-oncology*. 2001; 54(3): 277-86. Epub 2002/01/05.
  - [16] Nicholson JC, Punt J, Hale J, Saran F, Calaminus G. Neurosurgical management of paediatric germ cell tumours of the central nervous system--a multi-disciplinary team approach for the new millennium. *British Journal of neurosurgery*. 2002; 16(2): 93-5. Epub 2002/06/06.

